

## Leiomyoma of Epididymis : A Case Report

DESHPANDE R. H\*, Paithankar K. B.

Department of Pathology, MIMSR Medical College, Latur, Maharashtra (India)

\*Corresponding Author Email: [drshamhd@gmail.com](mailto:drshamhd@gmail.com)

**BIOLOGICAL SCIENCES**

RECEIVED ON 05-04-2012

**RESEARCH ARTICLE**

ACCEPTED ON 18-04-2012

### ABSTRACT

Aim of the article was to present a very rare case of leiomyoma of epididymis. As per the clinical protocol and investigations done from departments of radiology and pathology. Result of leiomyoma of epididymis was confirmed after histopathological report. Tumours of the epididymis, both primary & secondary, whether benign or malignant are very rare. We report a case of Leiomyoma of epididymis in a forty one years old male. Only FNAC and Sonography examinations are not sufficient, in diagnosing such cases, further investigation like histopathology should be planned.

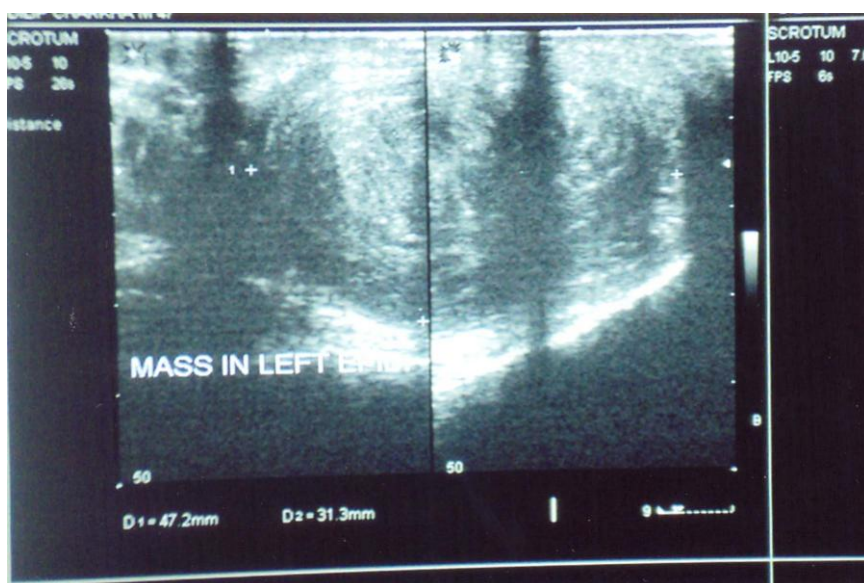
**KEYWORDS:** Epididymis, Leiomyoma, Benign tumour., Malignant tumors

### CASE REPORT

A 41 years old male presented with left testicular swelling since two years. Swelling was nontender, firm and hard in consistency having size of 4 cm. X 2 cm. FNAC (Fine needle aspiration cytology ) was done, which was suggestive of chronic inflammatory lesion (Tuberculosis). There was no involvement of

inguinal or supraclavicular lymph nodes. Patient was treated with antituberculous therapy for two and half months, but no response was shown by the patient. So ultrasonography was advised, which reported a heterogenous mass of 47 x 32 mm size at the lower pole of epididymis (Fig. 1).

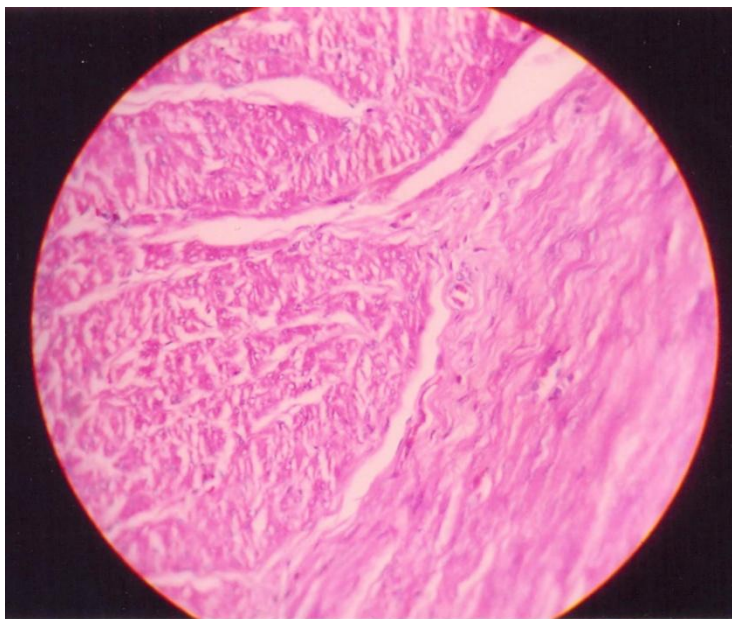
**Fig.1: Sonographic picture showing heterogenous mass in left epididymis.**



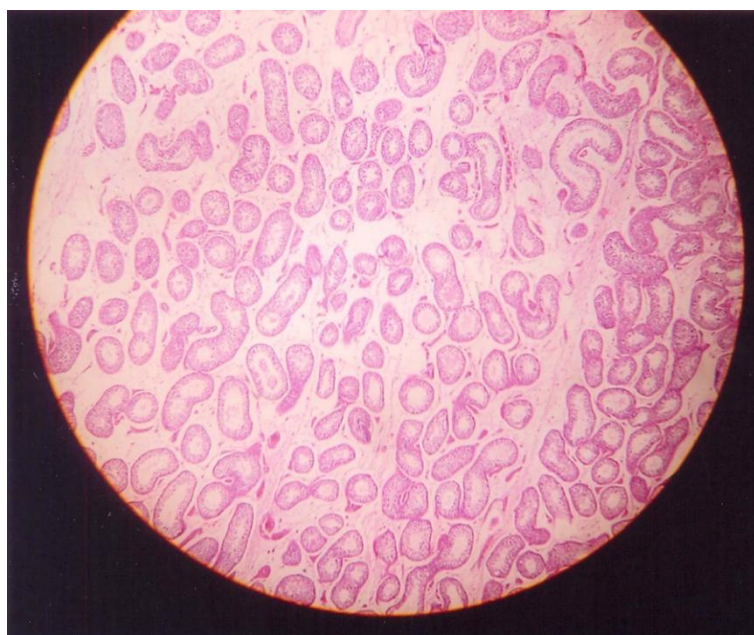
It was decided to remove the mass and left orchidectomy was done. Sample was send to histopathological examination. Section from mass showed bundles of smooth muscle cells seperated by thin fibrous septae.(Fig. 2)

Section from testis showed normal appearing seminiferous tubules (Fig. 3) There was no evidence of granuloma or malignancy. So the case was reported as Leiomyoma of epididymis.

**Fig.2: (H & E stain – x 40) Microscopic picture showing the smooth muscle cells arranged in intersecting fascicles separated by fibrous septae**



**Fig. 3: Microscopic picture of testis showing normal seminiferous tubules.**



## DISCUSSION

Leiomyomas are benign often bulky tumours that are derived embryologically from mesenchymal cells. Although rare in genitourinary tract, leiomyoma can originate from any structure containing smooth muscles, most commonly the renal capsule<sup>1</sup>. Primary, solid neoplasms of epididymis are also rare and leiomyomas of epididymis are even more rare in occurrence<sup>2-3</sup>.

When patient presents with any scrotal mass, a diagnostic and therapeutic problem arises from the concern over a possible malignancy. In this case mass was firstly diagnosed as chronic inflammatory lesion (Tuberculosis) and patient was treated with antituberculous therapy. for two and half months, but no response was shown by the patient. Then ultrasonography and histopathological examination was carried out, which labeled the lesion as leiomyoma of epididymis. Therefore any scrotal mass must be appropriately evaluated for the possibility of malignancy-keeping in mind, however, that extra testicular masses are typically secondary to trauma, infection and inflammation or benign neoplasms<sup>4</sup>. Primary, solid neoplasms of epididymis account for only 5 % of scrotal masses<sup>5</sup>. One must remember that approximately 20 % paratesticular masses are malignant<sup>6</sup>. Differential diagnosis of benign masses includes adenomatoid tumors, fibromas, leiomyomas and papillary

cystadenoma. The incidence of leiomyoma of epididymis in white people is estimated to be 5 % of epididymal masses , as apposed to 40 % in Asian people<sup>7</sup>.

Leiomyomas of epididymis have been reported from different countries and mentioned it as rare presentation<sup>7-10</sup>.

These results indicate that when a patient with scrotal mass swelling is there, such rare causes like leiomyoma of epididymis, should be kept in mind. As only FNAC and Sonography examinations are not sufficient, in diagnosing such cases, further investigation like histopathology should be planned.

## ACKNOWLEDGEMENTS

The authors wish to thank Dr. B.S. Nagoba, Dr. A. S. Yadav and Mr. V. N. Kale, MIMSR Medical College, Latur for their co-operation in the preparation of manuscript.

## REFERENCES

1. Chiang Et al (2004): Uncommon benign intrascrotal tumours. (Ann Acad Med. Sing 33: 351-355)
2. Micahel J Fumo, Osama Al Assi, Stiphen lireff: Leiomyoma of the epididymis treated with partial epidedactomy: Nature clinical practice urology (2006, 3, 504-507)
3. Juan Rosai: Ackerman's surgical pathology : seventh edition , volume two, published by the civ mosby company, Washington

4. Feld Rand Middleton WD (1992): Recent advances in sonography of the testis and scrotum: Rediol Chin North Am, 30, 1033-1051.
5. Yeager B A et al (1989): The impact of sonography on the management of extratesticular abnormalities of the scrotum: J. Clin Ultrasound, 17, 573-577.
6. Lioe T.F. and Biggart J.D. : Tumors of the spermatic cord and paratesticular tissue – A clinicopathological study : Br-J-Urol 71, 600-606, 1993.
7. Block AR and Block NL : Leiomyoma of epididymis : March-1995, J.Urol 153 : 1063-1065.
8. S.K.Wong : Leiomyoma of epididymis : Singapore Med J. ,1999, Vol 40 (08).
9. Murat sozlu, dichlehan orhan, summer baltacic : Leiomyoma of epididymis : Internal Urology and nephrology : Vol. 32, No.11 , 95-96.
10. H Sin-.chin Yeh, Wen-jena wu, Yung-chirlee : Leiomyoma of epididymis- A case report : the Kaobsinlang J.of Medcal Sciences , Oct-2006, vol.22,issue 10, page 519-523.



**\*Corresponding Author:**

**Dr. DESHPANDE R. H.**  
*Associate Professor of Pathology,  
MIMSR Medical College,  
Latur – 413 531 (M.S.) India*